

See discussions, stats, and author profiles for this publication at: <https://www.researchgate.net/publication/268076388>

# Management of the Clinically Negative Neck in Oral Squamous Cell Carcinoma: A Systematic Review

Article in *Journal of Cancer Research and Therapeutic Oncology* · September 2014

DOI: 10.117303/jcrto.2014.302

---

CITATIONS

7

READS

263

1 author:



Ayman F Hegab

Al-Azhar University

56 PUBLICATIONS 318 CITATIONS

SEE PROFILE

Some of the authors of this publication are also working on these related projects:



TMJ SURGERY [View project](#)



A novel approach for Intra-oral removal of submandibular gland stone: advantage and limitations [View project](#)

# Management of the Clinically Negative Neck in Oral Squamous Cell Carcinoma: A Systematic Review

Ayman F. Hegab \*, Mohamed Elmasry, Mustafa G. Khallaf

Oral & Maxillofacial Surgery, Faculty of Dental Medicine, Al-Azhar University in Cairo, Egypt

\*Corresponding author: Ayman F. Hegab, Associate professor of Oral & Maxillofacial Surgery, Faculty of Dental Medicine, Al-Azhar University in Cairo, Egypt. Email: hegab@mail.com

Received Date: December 14, 2013; Accepted Date: September 12, 2014; Published Date: September 18, 2014

Citation: Ayman F Hegab, et al. (2013) Management of the Clinically Negative Neck in Oral Squamous Cell Carcinoma: A Systematic Review. J Cancer Res Therap Oncol 2: 1-12

## Abstract

The decision regarding treatment of the clinically negative neck has been debated extensively. The aim of the current review was to answer the following questions: What is the optimal pre-treatment modality for diagnosing the cervical lymph nodes metastasis? Should a patient with a cN0 neck treated now or wait and see? Should the patient receive an elective neck dissection or should they be treated with elective neck radiation? Are there prognostic factors that can guide us in our decisions in treating the neck? Which modality should be used for treating the neck? What are the future trends?

**Material and Methods:** A computer literature search in MEDLINE, EMBASE, the Cochrane library and CENTRAL databases followed by extensive hand searching for identification of the relevant studies. The inclusion criteria include the following: the study should include patients treated for clinically negative neck of OSCC, report the management of the initial OSCC, include a comparison of the diagnostic methods for the neck metastasis in OSCC, and include comparison of different methods for treatment of the clinically negative neck of OSCC. 27 studies were eventually identified and systematically reviewed.

**Results:** 27 studies fulfilled the inclusion criteria. A total of 3867 patients were reviewed (neck dissection= 2291 with recurrence in 148 patients, wait and see = 1523 with recurrence in 406 patients, radiotherapy = 11 with recurrence in 6 patients, combined therapy 42 with recurrence in 9 patients). Conclusion: based on the results of the current study, it seems the neck dissection superior to wait and see policy. Sentinel lymph node biopsy superior to Ultrasonography-guided cytology.

**Keywords:** Oral squamous cell carcinoma; Clinically negative neck; Sentinel lymph node biopsy; Neck dissection; Ultrasound-guided fine-needle aspiration cytology

## Introduction

Oral cancers have a high potential of spreading to cervical lymph nodes. Therefore one of the most important factors affecting long-term survival is the clinically manifest cervical lymph-node status at the time of diagnosis [1,2].

When nodal metastases are present, nobody can deny the important effect of therapeutic neck dissection in the prognosis of head and neck cancer patients. However, Management of the cN0 in oral cancer has been a matter of discussion. Even in the absence of clinical proven metastases (cN0), there is generally a high rate of occult metastases, which strongly depends on the localization as well as the extent of the primary tumor. Management of the cN0 neck is therefore considered crucial. Several publications of surgically treated patients have provided pathological data allowing estimating the

risk for subclinical nodal involvement (i.e. occult metastases), which ranges from 5% to 62.2%. [3-5] Such estimates of risk are an important basis for rationally based decisions as to which loco-regional treatment concepts should be used [6]. The N0 neck can be treated electively or can be carefully observed (wait-and-see), and the decision is based on risk calculations and clinical experience. Historically, treatment ranged from elective radical neck or elective radiation of the neck to watchful waiting policy.

## Material and Methods

### Search Strategy

A computer literature search in MEDLINE, EMBASE, the Cochrane library and the Cochrane Central Register of Controlled Trials (CENTRAL) databases was performed by two of the reviewers (A.H. and M.E.) in order to identify the studies that answered the questions of interest. For this purpose the following free-text terms were used: Oral Squamous Cell Carcinoma, Clinically Negative Neck, Sentinel Lymph Node

Biopsy, Wait and See Policy or observation, ultrasound-guided fine-needle aspiration cytology. There were no restrictions regarding time and language. Additionally, extensive hand searching of the references of all the relevant studies was also performed.

### Selection of the studies

All the criteria for inclusion/ exclusion of the studies in the present systematic review were specified prior to the literature search. In order for the current study to be eligible, the following criteria were established. The inclusion criteria include the following: the study should include patients treated for clinically negative neck of OSCC. The study should report the management of the initial OSCC. The study should include a comparison of the diagnostic methods for the neck metastasis in OSCC. The study should include comparison of different methods for treatment of the clinically negative neck of OSCC. The studies that not offer the inclusion criteria were excluded from the systematic review.

### Studies identified

The electronic search resulted in the identification of 976 publications. Subsequently, the titles of these manuscripts were examined to exclude the irrelevant studies, which resulting in 281 potentially eligible publications. The abstracts of these studies were evaluated and only 61 studies were included in the current systematic review, which could provide data to answer the research questions. Eventually, only 27 studies were matched the inclusion criteria and they were assessed independently by two of the reviewers (A.H. and M.E.). (Table 1) [7-33]. The studies excluded because they did not properly address the research questions, or they did not include appropriate statistical analysis, they were letters to editor, case report or reviews.

### Data extraction

Data extraction was performed by two of the reviewers (A.H. and M.E.). The following data was recorded from the included studies: type of the study, number of patients included in the study, type of diagnostic procedures, type of management of the neck (neck dissection, radiotherapy, wait and see policy or combination therapy) and recurrence or failure.

Two reviewers independently assessed the methodological quality of each article in term of internal and external validity, based on the recommendation of the Cochrane handbook of for systematic reviews of interventional [34].

### Results

27 studies fulfilled the inclusion criteria. The studies published between 1999 and 2013. 15 studies were prospective studies while the other 12 studies were retrospective studies. A total of 3867 patients were reviewed (neck dissection= 2291 with recurrence in 148 patients, wait and see = 1523 with recurrence in 406 patients, radiotherapy = 11 with recurrence in 6 patients, combined therapy 42 with recurrence in 9 patients). Sentinel lymph node biopsy was used in 734 with failure in 19 patients while ultrasonography-guided cytology (USgFNAC) was used in 1107 with failure or recurrence in 236 patients (Table 2).

## Discussion

### The problem

It is well known that 6% to 46% of patients with head and neck cancer who have no palpable disease in their necks will harbor occult disease in their necks [35]. Beside, Cervical nodal staging is a major challenge. Basic studies by Lindberg [36] and Shah [37] demonstrated that SCCOC lymphatically tends to spread in a predictable way. According to Shah, who performed 192 radical neck dissections in patients suffering from oral cancer having a cN0 neck (with no clinically palpable metastases), these tumors mainly spread to level I-III [37]. These findings indicate that selective removal of the nodes in these specific levels should remove the vast majority of possibly tumor-positive nodes. However, a number of authors [38-40] emphasize that 'skip metastases' occur in a considerable amount of treated cN0 oral cancer patients: in these patients level I and II were not affected, while III and/or IV were. No consensus has been reached yet and the extent of neck dissection varies per medical center.

Clinical examination is influenced by the skill of the examiner, the patient's body habits and whether the patient has had previous surgical or irradiation therapy. As a result of these factors, clinical examination associated with high rate of false negative, and should be supplemented with diagnostic tools like CT scan and ultrasonography [41].

Also, there is no method of pretreatment imaging or other examination that will detect microscopic foci of metastatic disease in cervical lymph nodes. Immunohistochemical and molecular analysis of neck specimens reveals the incidence of occult metastases to be higher than revealed by light microscopy with ordinary hematoxylin and eosin staining. Occult regional metastasis may be found even in cases with small primary tumors.

### Management issues

Controversies in the treatment of negative neck in oral cancer arise due to different question that facing the surgeons treating such cases, these issues include the following: What is the optimal pre-treatment modality for diagnosing the cervical lymph nodes metastasis? Should a patient with a cN0 neck treated now or wait and see? Should the patient receive an elective neck dissection or should they be treated with elective neck radiation? Are there prognostic factors that can guide us in our decisions in treating the neck? Which modality should be used for treating the neck? What are the future trends?

The answer is continuously debated, but surgeons believe management decisions should rely on the incidence of occult metastatic disease for a given tumor and its sub site. Finally, the decisions to treat a clinically negative neck should be based on the risk- benefits of the morbidity associated with treatment and the incidence of occult metastases for a given primary [42-44].

### What is the pre-treatment modality for diagnosing the cervical lymph nodes metastasis?

The Study	Type of the study	No of cN0 patients	Type of diagnostic procedures	Type of management of neck	Recurrence Or failure
G.B Flach et al -2013(7)	Retrospective	285	USgFNAC	W&S =234 ND =51	W&S =65 ND =20
O'Connor R et al-2013 (8)	Prospective	481	SLNB	ND	12
P. W. Poeschl et al- 2012(9)	Retrospective	74	C.T-MRI	ND	13
Martin Canis et al;-2012(10)	Retrospective	425	C.T-MRI	W&S =223 ND =202	W&S =16 ND =10
Didier & Philippe -2011(11)	Prospective	21	C.T-MRI	ND	2
Bart M. Wensing et al-2011(12)	Retrospective	197	USgFNAC	W&S	48
David M. Montes et al -2011(13)	Retrospective	109	C.T-MRI	W&S= 61 ND= 48	W&S=9 ND=11
Civantos et al-2010(14)	prospective	140	C.T-MRI	ND	7
B.M Wensing et al-2010(15)	Retrospective	224	USgFNAC-US	ND	40
Yuen Apet al -2009(16)	Prospective	71	USgFNAC-US	W&S=35 MD=36	W&S=13 ND=2
M. Okura et al-2009(17)	Prospective	165	C.T-MRI	W&S=118 ND=47	W&S=25 ND=2
Keski-Säntti H et al-2008(18)	Prospective	13	SLNB	W&S=11 ND=2	0
Huang et al-2008(19)	Retrospective	380	C.T-MRI-US	W&S=556 ND=324	W&S=16 ND=40
E. M.Lype et al-2008(20)	Retrospective	161	C.T-MRI-US	ND=119 ND+RT=42	ND=11 ND+RT=9
Borgemeester MC et al- 2008(21)	Retrospective	163	USgFNAC-US	W&S=37 ND=126	W&S=17 ND=21
Ana Capote et al-2007(22)	Retrospective	154	C.T-MRI-US	W&S=67 ND=87	W&S=18 ND=7
H. Keski et al-2006(23)	Retrospective	80	C.T-MRI-US	W&S=34 ND=46	W&S=15 ND=9
Ng et al-2006(24)	Prospective	134	C.T-MRI- [18F]FDG PET-CT	ND	0
Wensing et al- 2006(25)	Prospective	30	US followed by [18F]FDG PET-CT	ND	6
Robert D. Hart et al-2005(26)	Prospective	20	SLNB	ND	0
Alexandru & lidia -2004(27)	Retrospective	185	C.T-MRI	W&S= 154 ND=20 RT=11	W&S=99 RT=6
T. Poli et al-2003(28)	Prospective	10	SLNB	ND	0
Sato Eida et al-2003(29)	Prospective	58	Combination CT & US	W&S	17
Nieuwenhuis EJ et al-2002(30)	Prospective	161	USgFNAC	W&S	34
Rodeny J Taylor et al-2001(31)	Prospective	9	SLNB	ND	0
Shoaib T et al- 2001(32)	Prospective	40	SLNB	ND	0
Michiel W.M et al- 1999(33)	Prospective	77	USgFNAC	W&S	14

**Table 1:** studies included in the current systematic review

Type of intervention	No. of the patients	Failure or recurrence
Neck dissection	2291	148
Wait and see policy	1523	406
Radiotherapy	11	6
Combined therapy	42	9
Sentinel lymph node biopsy	734	19
Ultrasonography-guided cytology (USgFNAC)	1107	236

**Table 2:** type of intervention, no. of patients and failure or recurrence in the studies included in the current systematic review

Ideally, the decision about treatment of an N0 neck would be simplified if there were a highly accurate, noninvasive diagnostic modality that could identify metastatic lymph nodes. Studies have shown that the sensitivity, specificity, and accuracy of detection of neck metastases by clinical examination are 70%, 65%, and 68%, respectively. The assessment of the status of the neck nodes is often based on palpation, although this is generally accepted to be inaccurate. The overall error in the assessment of the presence or absence of cervical lymph node metastasis is 20 to 30%. Histopathological evaluations have demonstrated that both the false-positive and the false-negative rate are unsatisfactorily high, causing over- and under treatment in many patients [45].

Modern imaging techniques, such as computed tomography (CT), magnetic resonance imaging (MRI), ultrasound (US) and especially US-guided fine-needle aspiration cytology, are more reliable than palpation [46].

CT and MRI are widely used to stage the neck but are limited by the facts that the size of the lymph nodes must be at least 5 mm before they can be detected by either of these modalities, cellular metastatic disease may not produce gross changes in the node, and even grossly abnormal nodes may remain undetected in some examination. MRI, by virtue of its high contrast resolution and multiplanar capacity, has advantages over CT for staging primary tumors of the head and neck region, while CT is faster, cheaper, and marginally more accurate than MRI in staging cervical nodes [47].

Dynamic contrast-enhanced MRI has been applied for differentiating normal from metastatic lymph nodes. [48] This approach measures the amount of contrast medium accumulating within a node versus time after bolus intravenous contrast administration, and evaluates alterations in nodal microcirculation. Compared with a normal node, a metastatic node has a longer time-to-peak accumulation of contrast medium, a reduced peak enhancement, a reduced slope of accumulation, and a reduced washout slope. Diffusion-weighted MRI has been investigated for characterizing cervical adenopathies based on the hypothesis that nodal metastases may be associated with alterations in water diffusivity and microcirculation. The apparent diffusion coefficient (ADC) for cancerous nodes is reported to be greater than that for benign nodes, which in turn is greater than that for lymphomas [49].

A novel MR contrast agent, known as ultrasmall superparamagnetic particles of iron oxide (USPIO), is classified as a nanoparticle composed of an iron oxide core. These nanoparticles have been employed to improve the ability of MRI to differentiate metastatic from benign nodes. Evaluation with USPIO requires 2 MR scans performed 24 hours apart. The first scan is used to identify the location of the lymph nodes. Twenty-four hours after injection of USPIO, a second MR scan is performed to evaluate the patterns of contrast enhancement of the identified lymph nodes [50].

With intravenous administration of USPIO, a normal node will phagocytize the particles and the entire node "blackens" on T2- and T2-weighted images obtained 24 h later. If a part of the node is infiltrated with tumor, such an intranodal area

does not uptake USPIO and, hence, does not blacken.

While CT and MRI have been more widely employed, and produce a comprehensive assessment of the neck in a single examination, US has an advantage over these other imaging techniques by its low cost, ease of use and excellent patient safety profile as it is noninvasive and avoids exposure to ionizing radiation. Because it can easily be used to direct a cytologic examination, US combined with fine-needle aspiration are gaining popularity. US has not, however, received universal acceptance because it is highly operator dependent and requires considerable training. To obtain a high sensitivity, suspicious lymph nodes with abnormal echogenicity, even as small as 4–5 mm, in the first two echelons should be aspirated. Van den Brekel et al. [51] found that in experienced hands the use of US-guided fine-needle aspiration cytology resulted in a sensitivity of 76% with a specificity of 100% in N0 necks.

Positron emission tomography (PET) with fluorodeoxyglucose (FDG) is increasingly used in preoperative staging of cancer patients. FDG depicts the increased metabolism of malignant cells as compared with normal cells. The PET scan is therefore a functional imaging technique based on a combination of advanced detection equipment and the use of radioactive tracers. Reports on the value of FDG-PET in detecting occult metastatic disease have been contradictory with a reported sensitivity ranging from 0% to 100% and specificity from 92% to 100% [50,52,53].

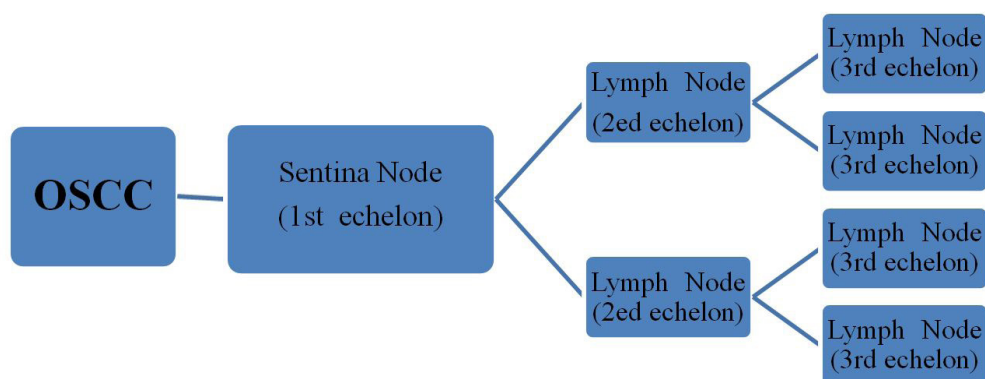
Ultrasound-guided fine-needle aspiration can provide cytologic analysis from nodes as small as 5 mm in diameter. It is a very accurate method for determining cervical metastasis, with a reported sensitivity of 90% and specificity of 100%. [54] De Bondt et al. [54] performed a meta-analysis comparing ultrasonography (US), US guided fine needle aspiration cytology (USgFNAC), computed tomography (CT), and magnetic resonance imaging (MRI) in the detection of lymph node metastases in head and neck cancer. They found that ultrasound-guided fine-needle aspiration cytology (USgFNAC) showed to be the most accurate imaging modality to detect cervical lymph node metastases. Ultrasound also performs well, whereas computed tomography and magnetic resonance imaging are less accurate.

### Sentinel lymph node biopsy (SLNBX)

The sentinel node concept states that the spread of a tumor is embolic in nature, via the lymphatics to the first echelon lymph node(s) encountered in the regional draining basin. These represent the lymph nodes most likely to harbor occult metastases, and are designated the sentinel lymph nodes (SLNs) (Figure 1).

Excisional biopsy and pathological evaluation of the SLNs therefore allows for prediction of the disease status of the remaining cervical lymph node basin, potentially avoiding the need for a neck dissection. Sentinel lymph nodes need not be those closest to the tumor, and there may be multiple SLNs. With the application of early dynamic lymphoscintigraphy, lymphatic channels are usually visualized, and nodes on a direct drainage pathway may be distinguished. The practical approach may include the combination of available detection





**Figure 1:** the concept of sentinel lymph node

techniques. The SN procedure consists of three steps: identification, surgical removal, and extensive Histopathological evaluation of the SN. Identification of the SN is possible after peritumoural injection of a radiopharmaceutical (referred to as tracer). In Europe, mainly  $^{99m}\text{Tc}$ -Nanocoll is used as tracer, but also other tracers have been used. The tracer consists of a colloid labeled to the gamma emitting radioisotope  $^{99m}\text{Tc}$ . The tracer is followed during migration, and uptake of the tracer in the first draining lymph node (the SN) is currently visualized by using a gamma camera or SPECT/CT (referred to as lymphoscintigraphy). The localization of the identified SN is marked on the skin. Surgical removal of the SN via a small incision is performed under handheld gamma probe guidance and, optionally, blue dye guidance. Of note, most centers perform the lymphoscintigraphy one day prior to surgery. The final step of the procedure is extensive Histopathological examination of the SN using step-serial sectioning and Immunohistochemical staining [55].

Gould et al. [56] reported the indication of neck dissection for parotid cancer using the word “sentinel lymph node” in 1960. They were surprisingly prescient to have foreseen the sentinel node concept of head and neck cancer more than 40 years ago. In 1977, Cabanas [57] described the sentinel node concept of penile cancer. Recently, many investigators in the head and neck field have been studying and reporting sentinel lymph node (SLN) localization and biopsy [55, 58-61].

The most important inclusion criterion for SNB is a clinically negative neck, as defined by physical examination and clinical imaging by computed tomography (CT), contrast-enhanced magnetic resonance imaging (MRI), ultrasound-guided fine-needle aspiration cytology (USg-FNAC), and/or  $^{18}\text{F}$ -fluorodeoxyglucose (FDG) positron emission tomography (PET) with or without low-dose CT (PET/CT).

The first and most frequent indication for SNB is to stage the ipsilateral cN0 neck in patients with a unilateral primary tumor. A second indication is for assessment of bilateral cN0 necks in primary tumors close to, or crossing, the midline. The third indication is for assessment of the contralateral cN0 neck in primary tumors close to the midline with an ipsilateral cN? neck, in order to decide whether these patients need bilateral neck dissections, or an ipsilateral neck dissection and contralateral SNB only. Patients should also be fit enough pre-operatively to withstand a neck dissection.

Patients who have received prior radiation or surgical treatment to the neck are routinely excluded from SNB protocols, since the previous intervention can distort the normal lymphatic pathways and give rise to unexpected patterns of metastasis. It is possible that lymphatic mapping and SNB may yield potentially useful information in these patients. Similarly, patients with small recurrent or second primary tumors may also benefit from lymphatic mapping to guide surgical intervention. However, these applications of the SNB technique, whilst clinically attractive, remain largely unexplored [62].

In pregnant women, the urgency and the necessity of staging the neck should be discussed. Lymphoscintigraphy is specifically contraindicated in the pelvis of pregnant women, but no such recommendations are currently available for the head and neck. The risk of fetal damage is negligible during routine SNB procedures. However, SNB protocols should be modified in pregnant patients to minimize risks of radiation exposure and blue-dye injections. For example, the use of a 1-day protocol allows a lower injected radiation dose, and the additional radiation associated with SPECT/CT imaging may not be warranted in the pregnant patient. SNB can be performed in lactating women, but it is advised that breastfeeding be discontinued following the procedure [62].

Staging of cancers by sentinel lymph node identification and biopsy is based on the concept that metastasis from a primary tumor occurs by predictable orderly spread. The first to receive the metastatic spread will be the first echelon node before filtering to the remainder of the lymphatic basin. Therefore, identification and histopathologic examination of the sentinel node can define the disease status of the entire regional lymphatic nodal basin. SLNB involves preoperative lymphoscintigraphy, intraoperative lymphatic mapping using hand held gamma probe or vital blue dye and finally pathologic evaluation of the sentinel lymph node. Patients who have N0 head and neck cancer may benefit most from SLNBX. Approximately 20% to 40% of patients who have N0 disease harbor microscopic tumor foci. Thus, approximately two thirds of patients who have N0 head and neck cancer will have no pathologic evidence of metastatic disease. Taking a “wait and see” approach in patients with N0 cancer has been associated with disease recurrence and a worsened prognosis. SLNBX has the potential of avoiding either overtreatment or undertreatment of the neck. In addition, SLNBX has the added benefit of improved disease staging by directing the pathologist to the “highest risk” lymph

node or nodes, which may be more extensively evaluated by either immunohistochemical or molecular techniques [63].

The sentinel lymph node is likely to be the first lymph node to harbour metastasis and can be used to provide information on the rest of the nodal basin. It is usually identified by peritumoral injection of radioactive colloid and blue dye. Preoperative lymphoscintigraphy, intra operative visualisation of blue colouration, and intra operative radionuclide detection with a gamma probe allow identification of the sentinel lymph node. After surgical removal, this node is studied meticulously by histopathological examination, using stepped serial sectioning and immunohistochemistry [64].

In summary, SNB is currently indicated for cT1/2, cN0 oral, and select oropharyngeal SCC, where it may be considered a valid alternative to elective neck dissection. Other head and neck sites, histologies, and clinical situations remain under investigation.

Recently, the use of near-infrared (NIR) fluorescent light has been introduced to intraoperatively identify lymph nodes, tumors and vital structures. NIR fluorescence using the fluorescent dye indocyanine green (ICG) has been successfully used for sentinel lymph node mapping in breast cancer, melanoma, cervical cancer, and vulvar cancer. [65-68] The concept of NIR fluorescence guided SLN mapping in oropharyngeal cancer has also been reported in humans [62].

Advantages of SLNB; improves the accuracy of tumor staging, minimally invasive procedure, avoid unnecessary nodal dissection, and limited morbidity and mortality with negative predictive value of 90-95%.

Disadvantages includes; unlike small primary tumors, a bulky invasive primary tumor invades adjacent anatomic subsites thus posing difficulty for peritumoral injection, proximity of primary tumor to the draining lymphatic basin, as is seen in floor of the mouth tumors, clinically positive nodes are difficult to be identified by sentinel node mapping because of the poor uptake of tracer; instead they redirect the entire lymphatic flow. Additional second stage surgery needed in case of positive neck node [62].

If proposed as a staging method, SNB should be feasible and reliable enough to replace elective neck dissection. SNB may prevent patients from unnecessary neck dissection and thereby from shoulder morbidity, pain and sensibility disorders which negatively influence health-related quality of life [69]. Moreover, if patients are prevented from neck dissection, a barrier to cancer spread is preserved in case of recurrence or second primary tumor. If proposed as a lymphatic mapping method, SNB may assist elective neck dissection by determining the neck side and levels that should be dissected. As an assistant in lymphatic mapping, SN identification may also assist the histopathological examination of the neck dissection specimen. If SN's are marked in the specimen, these specific lymph nodes can be step-serially sectioned and stained by immunohistochemistry leading to more accurate staging of the neck by the possibility of detecting more reliable micrometastases or isolated tumor cells [14,70].

Civantos et al conducted study to compared two surgical tech-

niques for evaluating the cervical lymphatics. The negative predictive value of SLNB, defined as the proportion of patients with negative sentinel nodes who were negative with respect to other nodes in the neck, was 96% for a population of T1 and T2 oral cancers. For T1 lesions, and for more experienced surgeons, the negative predictive value was 100%. They concluded that; it is reasonable to initiate clinical trials involving SLNB, with completion ND only for patients with positive sentinel nodes, as a lower morbidity approach for selected patients' with T1 and T2 oral cancers [14].

In the USA the cost of treating head and neck cancer is significant when compared with other solid tumors, only surpassed by lung and ovarian cancer [71]. In Germany and the USA the estimated cost was €893 million and €1.0 to 1.9 billion per year respectively [72], and in France the estimated cost was €530.5 million [73], with OSCC contributing 25% to the total. Per patient the cost of treatment between 1994 and 1996 in the Netherlands was €25,425 with 10 years follow up where appropriate [74].

There are only few studies that have looked at the economic advantage of head and neck cancer treatment using SLNB. O'Connor et al. [8] compared two management approaches, the traditional surgical pathway and SLNB pathway. Using SENT trial data regarding the proportion of patients with positive, negative and false negative SLNB's a relative cost ratio (RCR) for 100 hypothetical patients passing down each pathway was generated. The results from a cohort of 481 patients showed that, 25% had a positive SLNB, 75% a negative result and 2.5% a false negative result. Treatment of 100 hypothetical patients using the SLNB pathway is 0.35-0.60 the cost of treating the same cohort using traditional surgery techniques. Even if 100% of SLNB's are positive the SLNB approach is 0.91 of the cost of the traditional surgical approach.

In 2013, Govers et al. [75] performed comparative study to assess the cost-effectiveness of five strategies for diagnosing and treating cT1-2N0 oral squamous cell cancer. A Markov decision analytic model was used to evaluate the cost-effectiveness of elective neck dissection (END), watchful waiting (WW), gene expression profiling (GEP) followed by neck dissection (ND) or WW, sentinel lymph node (SLN) procedure followed by ND or WW, and GEP and SLN (for positive GEP) followed by ND or WW. Uncertainty was addressed using one-way and probabilistic sensitivity analyses. Base-case analysis showed that SLN procedure followed by ND or WW was the most effective and most cost effective strategy. SLN was found to have the highest probability (66%) of being cost-effective of the five strategies.

### **Should a patient with a cN0 neck treated now or wait and see?**

There is great controversy regarding the treatment for clinically negative necks. The protagonists of observation cite the morbidity of END as a reason to observe. Another argument for close observation is that with close follow-up, any cervical metastasis can be detected early and then treated with adequate therapy. Furthermore, the occult metastatic rate to the neck from oral cavity cancer is 34%. Hence, it is argued that nearly two thirds of the patients would be exposed to the mor-

bidity of a neck dissection unnecessarily [76].

A decision-tree analysis was created by Weiss et al [77] based on an analysis of the utility of the management options taking into account the incidence of node involvement, complications of treatment, and disease control rates. They concluded that observation is the preferred option when the probability of occult metastasis is less than 20% and elective neck treatment (irradiation or dissection) is preferred if the probability of occult metastasis is greater than 20%. In squamous cell carcinoma of the oral cavity the sites with a less than 20% occult metastatic rate to the neck are T1/T2 lip carcinomas, T1/T2 oral tongue carcinomas that are less than 4 mm thick, and T1/T2 floor of mouth cancers less than or equal to 1.5 mm thick. Weiss et al [77] have however alluded that the values will change and the threshold will be altered with the times.

On the other hand; the proponents of surgical intervention also note that removal of lymph nodes can be used as a staging procedure. If there is presence of extra capsular spread, the patient can be upstaged and receive more aggressive therapy early on rather than later when survival may be adversely affected. Andersen et al. [78] demonstrated that 77% of patients with clinically N0 necks at initial observation had pathologically adverse findings at the time of neck dissection. Furthermore 49% of these patients had ECS, a poor prognostic factor. Hence, they argued for elective neck treatment (irradiation or neck dissection) in patients with N0 necks.

The decision to observe or treat the N0 neck is left to the choice of the patient and the head and neck oncologist, in oral cavity carcinoma the only clinically N0 necks for which observation is appropriate are those associated with T1/T2 lip carcinomas, T1/T2 oral tongue carcinomas that are less than 4 mm thick, and T1/T2 floor of mouth cancers less than or equal to 1.5 mm thick [78].

### **Should the patient receive an elective neck dissection or should they be treated with elective neck radiation'?**

The issue of the use of elective surgery versus elective radiation ends not at which treatment modality is more beneficial, but which one is less harmful. The patient's age, general health, family support, reliability and patient's own wishes are important.

The reasons for using END are; Neck dissection has low morbidity & mortality, Cure rate for neck dissection is decreased if lymph node enlargement occurs or multiple nodes appear. It is impossible to provide follow-up necessary to detect the earlier conversion of a neck from N0 to N1, Allowing the neck metastases to develop increases the incidence of distant metastasis. If neck has been entered to remove the primary it is better to perform an in-continuity resection and High incidence of occult metastatic disease while cons for END are; END results in a large number of unnecessary surgical procedures and is associated with inevitable morbidity. Cure rates are no lower if the surgeon waits for the neck to convert from N0 to N1, Careful clinical follow-up will allow detection of the earliest conversion from N0 to N1, END removes the barrier to the spread of disease and also has a detrimental immunological effect, and

Radiation is as effective as neck dissection in N0 neck [79].

Mendenhall et al. [80] showed that elective neck irradiation (ENI) reduced the neck failure rate in patients with controlled primary tumors and N0 necks from 18% to 1.9%. The dose of radiation varied from 50 Gy to 75 Gy in the upper neck and from 40 Gy to 50 Gy in the lower neck will control occult metastases in 90 to 95% of cases [86].

Although prospective evidence is lacking, retrospective data suggest that for most sites and for early lesions, elective nodal irradiation (ENI) and END offers equivalent local control. Proponents of ENI assert that the morbidity is low with limited soft tissue changes and does not have systemic ramifications. However, considerable acute adverse effects such as mucositis and xerostomia, together with late effects like endarteritis, radionecrosis etc .can occur. Systemic effects include suppression of humoral and cell mediated immunity [82].

In a trial to get the benefits of END and decrease the morbidity, Endoscopic neck dissections has been tried. It's oncological safety and usefulness in practice are other issues that need to be addressed [83].

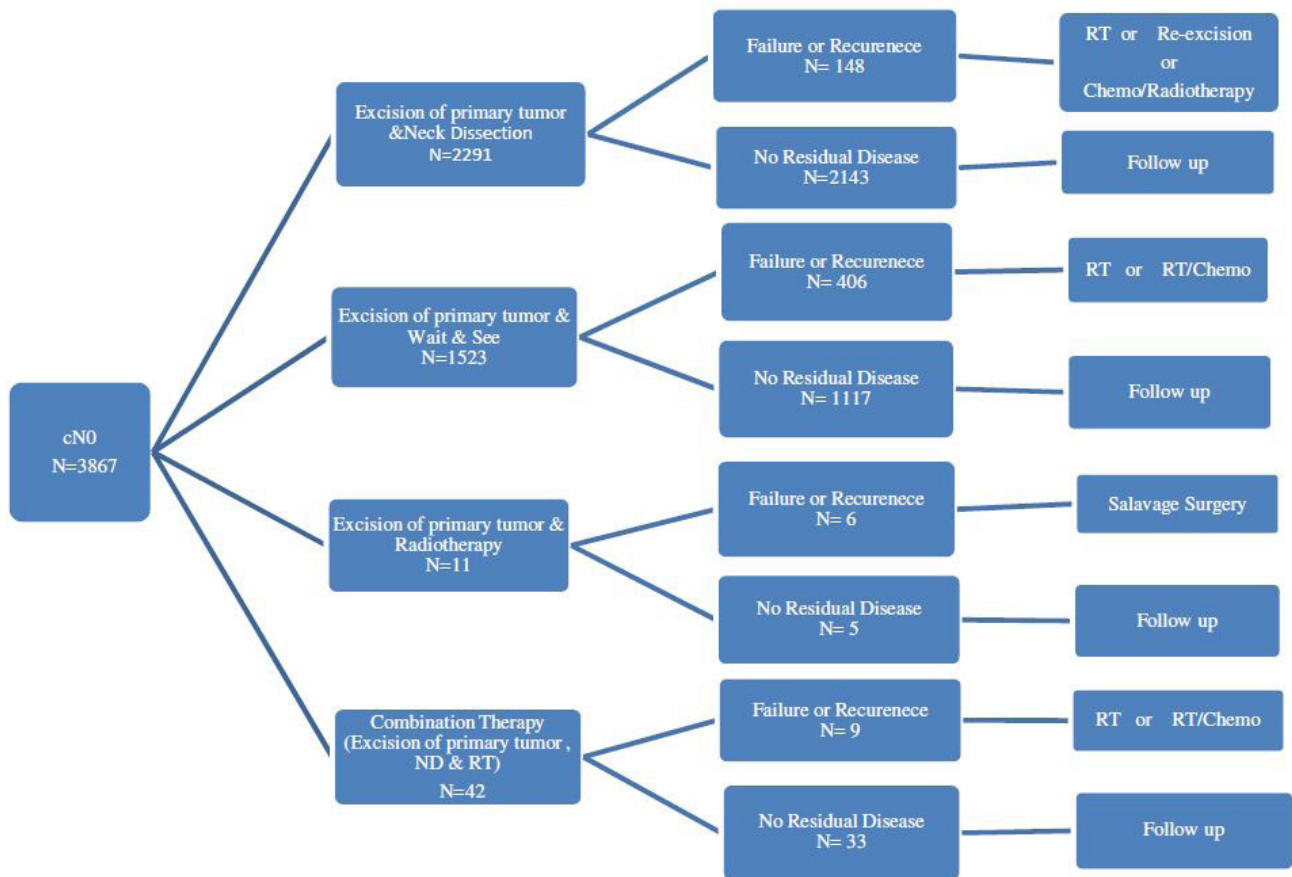
### **Are there prognostic factors that can guide us in our decisions in treating the neck?**

Vascular and lymphatic networks, which vary between different anatomic sites, may influence tumor evolution and the outcome. Higher metastatic disease rates for SCC at the base rather than at the oral tongue have been reported [84].

Leite and Koifman [85] showed higher mortality rates in patients with tongue carcinomas than in those who developed lip carcinomas. In addition, some anatomic sites are linked with poorer outcome owing to the rich lymphatic drainage and the local extension being hard to evaluate and manage, such as the superior gingiva-labial sulcus. [86] Also, The risk of nodal metastases and mortality rates vary directly with the thickness of the primary tumor [87].

The margin refers to how close the cancer cells are to the edge of the normal tissue surrounding the tumor. The presence of residual carcinoma at the margins of surgical resection is an important risk factor for local recurrence in OSCC. Positive margins indicated microscopically aggressive tumor biology. Margins of tumor could also be categorized as follows; Clinical margins: the margins of tumor on clinical examination that is on observation and palpation. It was always included during the surgical removal of tumor tissue. Surgical margins: The status of the surgical margin was an important predictor of outcome. The surgical margin, in contrast to the other prognostic indicators is under the direct control of the surgeon. Close surgical margins were considered as positive margins. High correlation existed between histological indicators of aggressive disease and close or involved surgical margins. These results implied that close surgical margins in OSCC could be regarded as an indicator of aggressive disease. Histological margins: Margins were described in the following three ways; Positive margins: Invasive tumor within 5 mm of final surgical margin. Cancer cells were involving the outer edge of tissue. Carcinoma in situ involved final surgical margin. Dysplasia in-





**Figure 2:** Treatment Algorithm For clinically negative neck

involved final surgical margin. Negative margins: No cancer cells were seen at the outer edge. The standard negative measurement in most hospitals is 2 mm of normal tissue beyond the edge of the tumor. Close margins: Cancer cells were very nearby but did not involve the outer edge of tissue. Close margin lie between positive and negative margins [88]. Local recurrence rate, ranged from 64 to 84% for positive margins. The presence of positive margins predicted poor overall survival for oral cancer. Intraoperative use of frozen sections for determining margin status reduced the local recurrence. Patients with clear margins had a survival rate of 69% at 5 years compared to 58% with close and 38% with involved margins. Intraoperative use of frozen sections for determining margin status also reduced the local recurrence.

Molecular margins: With advanced technology like the use of molecular markers to predict the positivity of tumor front or outer edges of the excised tissue. It has actually proved to be an ideal method to determine the adequacy or extent of tumor tissue removal. Various molecular markers could also be utilized for this purpose [88].

Infiltration of perineural spaces occurs in up to 52% of OSCC. Mediated through Nerve Cell Adhesion Molecule (NCAM), on the surface of cancer cells which engage in homophilic binding with NCAM receptors (expressed by neural and perineural tissue) [89]. The presence of Perineural Invasion (PI) in primary tumor is a predictor for cervical metastasis, locoregional recurrence. Centripetal and centrifugal propagation of tumor cells along perineural spaces and away from primary tumor is responsible for local recurrence [90]. Most tumors

allow 2 centimeter (cm) of dissemination of tumor cells along perineural space, so malignant cells that evade surgical excision and radiotherapy, results in local recurrence. The relationship between PI and prognosis is independent of nerve diameter, so in all cases of OSCC, the pathological specimen should be examined for PI even in nerves less than 1 mm in diameter. Vascular invasion is defined as, "the presence of neoplastic cells within an endothelial cell lined channel." It occurs in more than 50% of head and neck squamous cell carcinomas. It correlates with the presence of concomitant cervical metastases and showed an increased risk of distant metastatic disease [91]. The skin of face and scalp is most commonly affected by metastases, suggesting that blood vessels and patterns of innervations may influence the spread of metastases [92].

### Which modality should be used for treating the neck?

Treatment modality of the primary cancer plays an important role in the decision as to how to treat the neck. If primary radiation therapy is used, ENI can be performed. If the neck is going to be entered to remove the primary tumor, an END can be performed. Obviously, the risks of ENI and END need to be considered on an individual basis for each patient. The most important factors in guiding this decision should be the patient's informed decision, physician and institution experience, risk of second primary occurrence in the future, and the modality chosen to treat the primary cancer. The results of our systematic review showed that, the total number of patients treated by neck dissection is 2291 with failure or recurrence in 148 patients and patients treated by wait and see policy is

1523 with failure or recurrence in 406, while patients treated by combined therapy were 42 and failure or recurrence in 9 patients. Radiotherapy was used in only 11 patients with failure or recurrence in 6 patients (Figure 2).

### What are the future trends?

Current assessment of lymph node metastasis in patients with head and neck squamous cell carcinoma is not accurate enough to prevent overtreatment. Previous studies have indicated that gene expression profiling can potentially help predict lymph node status in HNSCC and OSCC, in particular [93-95]. Such a signature [96,97] is completely independently verified in this large multicenter study that was performed in a CLIA/ISO-certified laboratory using a diagnostic array platform. The results indicate that the signature should be prospectively tested and applied alongside current clinical assessment to identify a subgroup of patients with OSCC for whom a watchful waiting strategy would be appropriate. Combining current clinical assessment with the expression signature would decrease the rate of undetected nodal metastases from 28% to 11% in early-stage OSCC. This should be sufficient to enable clinicians to refrain from elective neck treatment. A new clinical decision model that incorporates the expression signature is therefore proposed for testing in a prospective study, which could substantially improve treatment for this group of patients [98].

Risk stratification is important in cancer treatment because it provides information that may be used to select the most appropriate therapeutic approach. Several well-known Risk stratification systems are applied worldwide today [99,100]. Other Risk stratification systems based on prognostic factors also assist physicians to more confidently select treatment strategies; furthermore, they facilitate the selection of more homogeneous patient groups for clinical trials [101, 102].

### Conclusion

In conclusion, this systematic review revealed that, among the OSCC patients with cN0 neck dissection seem to be superior to the others treatment policies, followed by wait and see policy in terms of survival and control of neck disease. Sentinel lymph node biopsy seem to be superior to Ultrasonography-guided cytology in terms of diagnostic accuracy and postoperative recurrence or failure. SLN biopsy could potentially guide head and neck oncologists to the patient with N0 disease who would benefit most from selective neck dissection and prevent the morbidity of unnecessary neck dissection.

In comparison with US, CT & MRI, it seems that the US-gFNAC is the most reliable imaging technique to assess the presence of metastases in cervical lymph nodes in patients with head and neck cancer.

### Conflict of interest

None of the authors has any conflict of interest, financial or otherwise.

### References

1) Pimenta Amaral TM, Da Silva Freire AR, Carvalho AL, Pinto CA, Kowalski LP (2004). Predictive factors of occult metastasis and prognosis of clinical stages I and II squamous cell carcinoma of the tongue and floor of the mouth. *Oral Oncol* 40: 780–786.

2) Kurokawa H, Yamashita Y, Takeda S, Zhang M, Fukuyama H, et al. (2002). Risk factors for late cervical lymph node metastases in patients with stage I or II carcinoma of the tongue. *Head Neck* 24: 731–736.

3) Vijayakumar M, Burrah R, Sabitha KS, Nadimul H, Rajani BC (2011) To operate or not to operate N0 neck in early cancer of the tongue? A prospective study. *Indian J Surg Oncol* 2: 172-175.

4) Kaya S, Yilmaz T, Gürsel B, Saraç S, Sennaroglu L (2001). The value of elective neck dissection in treatment of cancer of the tongue. *Am J Otolaryngol* 22: 59–64.

5) Qi-Gen Fang (2013). Occult Node Metastasis in Early Tongue Squamous Cell Carcinoma. *Anaplastology* 6 -2161-1173.

6) Kalet IJ, Whipple M, Pessah S, Barker J, Austin-Seymour MM, et al. (2002). A rule- based model for local and regional tumor spread. *Proc AMIA Symp* 360–364.

7) Geke B, Flach M, Mark Tenhagen, Remco de Bree, Ruud H. Brakenhoff, Isaac van der Waal, et al. (2013). Outcome of patients with early stage oral cancer managed by an observation strategy towards the N0 neck using ultrasound guided fine needle aspiration cytology: No survival difference as compared to elective neck dissection. *Oral Oncology* 49: 157–164.

8) Rory O'Connor, Tom Pezier, Clare Schilling, Mark McGurk (2013). The relative cost of sentinel lymph node biopsy in early oral cancer. *J Craniomaxillofac Surg* 41: 721-727.

9) Paul W. Poeschl, Rudolf Seemann, Cornelia Czembirek, Guenter Russmueller, Irene Sulzbacher (2012). Impact of elective neck dissection on regional recurrence and survival in cN0 staged oral maxillary squamous cell carcinoma. *Oral Oncol* 48: 173–178.

10) Canis M, Plüquet S, Ihler F, Matthias C, Kron M (2012). Impact of elective neck dissection vs observation on regional recurrence and survival in cN0-staged patients with squamous cell carcinomas of the upper aerodigestive tract. *Arch Otolaryngol Head Neck Surg* 138: 650-655.

11) Didier Dequanter, Philippe Lothaire (2011). Characteristics of Patients with Upstaging by Sentinel Lymph Node Biopsy of the N0 Neck in Head and Neck Cancer. *Journal of Cancer Therapy*. 2: 285-287.

12) Wensing BM, Merks MA, Krabbe PF, Marres HA, Van den Hoogen FJ (2011). Oral squamous cell carcinoma and a clinically negative neck: The value of follow-up. *Head Neck* 33: 1400–1405.

13) Montes DM1, Carlson ER, Fernandes R, Ghali GE, Lubek J, et al. (2001) Oral Maxillary Squamous Carcinoma: An Indication For Neck Dissection In The Clinically Negative Neck. *Head Neck* 33: 1581–1585.

14) Civantos FJ, Zitsch RP, Schuller DE, Agrawal A, Smith RB, et al. (2010). Sentinel Lymph Node Biopsy Accurately Stages the Regional Lymph Nodes for T1-T2 Oral Squamous Cell Carcinomas: Results of a Prospective Multi-Institutional Trial. *J Clin Oncol* 28: 1395-1400.

15) Wensing BM, Merks MA, De Wilde PC, Marres HA, Van den Hoogen FJ (2010) Assessment of preoperative ultrasonography of the neck and elective neck dissection in patients with oral squamous cell carcinoma. *Oral Oncol* 46:87-91.

16) Yuen AP1, Ho CM, Chow TL, Tang LC, Cheung WY, et al. (2009). Prospective randomized study of selective neck dissection versus observation for N0 neck of early tongue carcinoma. *Head Neck* 31: 765-772.

17) Okura M, Aikawa T, Sawai NY, Iida S, Kogo M (2009) Decision analysis and treatment threshold in a management for the N0 neck of the oral cavity carcinoma. *Oral Oncol* 45: 908–911.

- 18) Keski-Santti H1, Kontio R, Leivo I, Törnwall J, Mätzke S, et al. (2008) Sentinel lymph node biopsy as an alternative to wait and see policy in patients with small T1 oral cavity squamous cell carcinoma. *Acta Otolaryngol* 128: 98-102.
- 19) Huang SF, Kang CJ, Lin CY, Fan KH, Yen TC, et al. (2008) Neck treatment of patients with early stage oral tongue cancer: comparison between observation, supraomohyoid dissection, and extended dissection. *Cancer* 112: 1066-1075.
- 20) Iype EM, Sebastian P, Mathew A, Balagopal PG, Varghese BT, et al. (2008) The role of selective neck dissection (I-III) in the treatment of node negative (N0) neck in oral cancer. *Oral Oncol* 44: 1134-1138.
- 21) Borgemeester MC, van den Brekel MW, van Tinteren H, Smelee LE, Pameijer FA, et al. (2008) Ultrasound-guided aspiration cytology for the assessment of the clinically N0 neck: factors influencing its accuracy. *Head Neck* 30: 1505-1513.
- 22) Capote A, Escorial V, Muñoz-Guerra MF, Rodríguez-Campo FJ, Gamallo C, et al. (2007). Elective neck dissection in early-stage oral squamous cell carcinoma--does it influence recurrence and survival? *Head Neck* 29: 3-11.
- 23) Keski-Santti H, Atula T, Törnwall J, Koivunen P, Mäkitie A (2006) Elective neck treatment versus observation in patients with T1/T2 N0 squamous cell carcinoma of oral tongue. *Oral Oncol* 42: 96-101.
- 24) Ng SH, Yen TC, Chang JT, Chan SC, Ko SF, et al. (2006). Prospective study of [18F]fluorodeoxyglucose positron emission tomography and computed tomography and magnetic resonance imaging in oral cavity squamous cell carcinoma with palpably negative neck. *J Clin Oncol* 24: 4371-4376.
- 25) Wensing BM, Vogel WV, Marres HA, Merckx MA, Postema EJ, et al. (2006) FDG-PET in the clinically negative neck in oral squamous cell carcinoma. *Laryngoscope* 116: 809-813.
- 26) Hart RD, Nasser JG, Trites JR, Taylor SM, Bullock M, et al. (2005) Sentinel lymph node biopsy in N0 squamous cell carcinoma of the oral cavity and oropharynx. *Arch Otolaryngol Head Neck Surg* 131: 34-38.
- 27) Bucur A, Stefanescu L (2004) Management of patients with squamous cell carcinoma of the lower lip and N0-neck. *J Craniomaxillofac Surg* 32: 16-18.
- 28) Poli T, Massarelli O, Bianchi B, Ferrari S, Corradi D, et al. (2003) Role of intra-operative sentinel lymph node biopsy in oral cavity and oropharynx squamous cell carcinoma: preliminary data. *Acta Otorhinolaryngol Ital* 23: 305-313.
- 29) Eida S, Sumi M, Yonetsu K, Kimura Y, Nakamura T (2003) Combination of helical CT and Doppler sonography in the follow-up of patients with clinical N0 stage neck disease and oral cancer. *AJNR Am J Neuroradiol* 24: 312-318.
- 30) Nieuwenhuis EJ, Castelijns JA, Pijpers R, van den Brekel MW, Brakenhoff RH, et al. (2002). Wait-and-see policy for the N0 neck in early-stage oral and oropharyngeal squamous cell carcinoma using ultrasonography-guided cytology: is there a role for identification of the sentinel node? *Head Neck* 24: 282-289.
- 31) Taylor RJ, Wahl RL, Sharma PK, Bradford CR, Terrell JE, et al. (2001) Sentinel node localization in oral cavity and oropharynx squamous cell cancer. *Arch Otolaryngol Head Neck Surg* 127: 970-974.
- 32) Shoaib T, Soutar DS, MacDonald DG, Camilleri IG, Dunaway DJ, et al. (2001) The accuracy of head and neck carcinoma sentinel lymph node biopsy in the clinically N0 neck. *Cancer* 91: 2077-2083.
- 33) van den Brekel MW, Reitsma LC, Quak JJ, Smelee LE, van der Linden JC, et al. (1999) Sonographically guided aspiration cytology of neck nodes for selection of treatment and follow-up in patients with N0 head and neck cancer. *AJNR Am J Neuroradiol* 20:1727-1731.
- 34) Cochrane handbook of for systematic reviews of interventions (2006) 4.2.6 p. 79-91.
- 35) Capote A, Escorial V, Muñoz-Guerra MF, Rodríguez-Campo FJ, Gamallo C, et al. (2007) Elective neck dissection in early-stage oral squamous cell carcinoma--does it influence recurrence and survival? *Head Neck* 29:3-11.
- 36) Lindberg R (1972) Distribution of cervical lymph node metastases from squamous cell carcinoma of the upper respiratory and digestive tracts. *Cancer* 29:1446-1449.
- 37) Shah JP, Candela FC, Poddar AK (1990) The patterns of cervical lymph node metastases from squamous carcinoma of the oral cavity. *Cancer* 66:109-113.
- 38) Byers RM, Weber RS, Andrews T, McGill D, Kare R, Wolf P (1997) Frequency and therapeutic implications of "skip metastases" in the neck from squamous carcinoma of the oral tongue. *Head Neck* 19:14-19.
- 39) Crean SJ, Hoffman A, Potts J, Fardy MJ (2003) Reduction of occult metastatic disease by extension of the supraomohyoid neck dissection to include level IV. *Head Neck* 25:758-762.
- 40) Medina JE, Byers RM (1989) Supraomohyoid neck dissection: rationale, indications, and surgical technique. *Head Neck* 11:111-122.
- 41) Mathan Mohan, George Paul, Sam Thomas, Mohamed Jaber (2010). Evaluation Of Neck Node Metastasis From Oral Cancer In An Indian Population- A Comparative Pilot Study. *Ibnosina J Med BS* 2: 14-23.
- 42) Mendenhall WM, Million RR, Cassisi NJ (1986) Squamous cell carcinoma of the head and neck treated with radiation therapy: the role of neck dissection for clinically positive neck nodes. *Int J Radiat Oncol Biol Phys.* 12:733-740.
- 43) Mendenhall WM, Million RR (1986) Elective neck irradiation for squamous cell carcinoma of the head and neck: analysis of time-dose factors and causes of failure. *Int J Radiat Oncol Biol Phys* 12: 741-746.
- 44) Scharukh Jalisi (2005). Management of the Clinically Negative Neck in Early Squamous Cell Carcinoma of the Oral Cavity. *Otolaryngol Clin N Am* 38: 37-46.
- 45) Zbaren P, Weidner S, Thoeny HC (2008) Laryngeal and hypopharyngeal carcinomas after (chemo) radiotherapy: a diagnostic dilemma. *Curr Opin Otolaryngol Head Neck Surg* 16:147-153.
- 46) Curtin HD, Ishwaran H, Mancuso AA, Dalley RW, Caudry DJ, et al. (1998) Comparison of CT and MR imaging in staging of neck metastases. *Radiology* 207:123-30.
- 47) Fischbein NJ, Noworolski SM, Henry RG, Kaplan MJ, Dillon WP, et al. (2003) Assessment of metastatic cervical adenopathy using dynamic contrast-enhanced MR imaging. *Am J Neuroradiol* 24:301-311.
- 48) Sumi M, Sakihama N, Sumi T, Morikawa M, Uetani M, et al. (2003) Discrimination of metastatic cervical lymph nodes with diffusion-weighted MR imaging in patients with head and neck cancer. *Am J Neuroradiol* 24: 1627-1634.
- 49) Rockall AG1, Sohaib SA, Harisinghani MG, Babar SA, Singh N, et al. (2005) Diagnostic performance of nanoparticle enhanced magnetic resonance imaging in the diagnosis of lymph node metastases in patients with endometrial and cervical cancer. *J Clin Oncol* 23: 2813-2821.
- 50) van den Brekel MW1, Castelijns JA, Stel HV, Luth WJ, Valk J, et al. (1991) Occult metastatic neck disease: detection with US and US-guided fine-needle aspiration cytology. *Radiology* 180:457-461.
- 51) Brouwer J, de Bree R, Comans EF, Castelijns JA, Hoekstra OS, et al. (2004) Positron emission tomography using [18F]fluorodeoxy-



- glucose (FDG-PET) in the clinically negative neck: is it likely to be superior? *Eur Arch Otorhinolaryngol* 261: 479–483.
- 52) Myers LL, Wax MK (1998) Positron emission tomography in the evaluation of the negative neck in patients with oral cavity cancer. *J Otolaryngol* 27: 342–347.
- 53) Hyde NC, Prvulovich E, Newman L, Waddington WA, Visvikis D, et al. (2003) A new approach to pre-treatment assessment of the N0 neck in oral squamous cell carcinoma: the role of sentinel node biopsy and positron emission tomography. *Oral Oncol* 39: 350–360.
- 54) de Bondt RB, Nelemans PJ, Hofman PA, Casselman JW, Kremer B, et al. (2007). Detection of lymph node metastases in head and neck cancer: a meta-analysis comparing US, USgFNAC, CT and MR imaging. *Eur J Radiol* 64: 266–272.
- 55) Alkureishi LW, Burak Z, Alvarez JA, Ballinger J, Bilde A, et al. (2009) Joint practice guidelines for radionuclide lymphoscintigraphy for sentinel node localization in oral/oropharyngeal squamous cell carcinoma. *Ann Surg Oncol* 16: 3190–3210.
- 56) Gould EA, Winship T, Philbin PH, Kerr HH (1960) Observations on a “sentinel node” in cancer of the parotid. *Cancer* 13:77–78.
- 57) Cabanas RM (1977) An approach for the treatment of penile carcinoma. *Cancer* 39: 456–466.
- 58) Alex JC, Sasaki CT, Krag DN, Wenig B, Pyle PB (2000) Sentinel lymph node radiolocalization in head and neck squamous cell carcinoma. *Laryngoscope* 110:198–203.
- 59) Zitsch RP 3<sup>rd</sup>, Todd DW, Renner GJ, Singh A (2000) Intraoperative radiolymphoscintigraphy for detection of occult nodal metastasis in patients with head and neck squamous cell carcinoma. *Otolaryngol Head Neck Surg* 122: 662–666.
- 60) Dünne AA, Kùlkens C, Ramaswamy A, Folz BJ, Brandt D, et al. (2001) Value of sentinel lymph node dissection in head and neck cancer patients without evidence of lymphogenic metastatic disease. *Auris Nasus Larynx* 28: 339–344.
- 61) Taylor RJ, Wahl RL, Sharma PK, Bradford CR, Terrell JE, et al. (2001) Sentinel node localization in oral cavity and oropharynx squamous cell cancer. *Arch Otolaryngol Head Neck Surg* 127: 970–974.
- 62) Tina Elizabeth Jacob, N Malathi (2013) Sentinel Lymph Node Biopsy in Patients with Oral Cancer. *Health Sciences* 4: JS004C.
- 63) Leusink FK, van Es RJ, de Bree R, Baatenburg de Jong RJ, van Hooff SR, et al. (2012) Novel diagnostic modalities for assessment of the clinically node-negative neck in oral squamous-cell carcinoma. *Lancet Oncol* 13: e554–e561.
- 64) Hutteman M, Mieog JS, van der Vorst JR, Liefers GJ, Putter H, et al. (2011) Randomized, double-blind comparison of indocyanine green with or without albumin premixing for near-infrared fluorescence imaging of sentinel lymph nodes in breast cancer patients. *Breast Cancer Res Treat* 127:163–170.
- 65) Hutteman M, van der Vorst JR, Gaarenstroom KN, Peters AA, Mieog JS, et al. (2011) Optimization of near-infrared fluorescent sentinel lymph node mapping for vulvar cancer. *Am J Obstet Gynecol* 206: 89. e1–e5.
- 66) Mieog JS, Troyan SL, Hutteman M, Donohoe KJ, van der Vorst JR, et al. (2011) Toward optimization of imaging system and lymphatic tracer for near-infrared fluorescent sentinel lymph node mapping in breast cancer. *Ann Surg Oncol* 18: 2483–2489.
- 67) van der Vorst JR, Hutteman M, Gaarenstroom KN, Peters AA, Mieog JS, et al. (2011) Optimization of near-infrared fluorescent sentinel lymph node mapping in cervical cancer patients. *Int J Gynecol Cancer* 21:1472–1478.
- 68) Bredell MG (2010) Sentinel lymph node mapping by indocyanin green fluorescence imaging in oropharyngeal cancer – preliminary experience. *Head Neck Oncol* 2: 31.
- 69) El Ghani F, Van Den Brekel MW, De Goede CJ, Kuik J, Leemans CR, et al. (2002) Shoulder function and patient well-being after various types of neck dissections. *Clin Otolaryngol Allied Sci* 27: 403–408.
- 70) Flach GB, Bloemena E, van Schie A, Hoekstra OS, van Weert S, et al. (2013) Sentinel node identification in laryngeal cancer: Feasible in primary cancer with previously untreated neck. *Oral Oncol* 49: 165–168.
- 71) Lang K, Menzin J, Earle CC, Jacobson J, Hsu MA (2004) The economic cost of squamous cell cancer of the head and neck: findings from linked SEER-Medicare data. *Arch Otolaryngol Head Neck Surg* 130: 1269–1275.
- 72) Lee JM, Turini M, Botteman MF, Stephens JM, Pashos CL (2004) Economic burden of head and neck cancer. A literature review. *Eur J Health Econ* 5: 70–80.
- 73) St Guily JL, Borget I, Vainchtock A, Rémy V, Takizawa C (2010) Head and neck cancers in France: an analysis of the hospital medical information system (PMSI) database. *Head Neck Oncol* 2: 22.
- 74) van Agthoven M, van Ineveld BM, de Boer MF, Leemans CR, Knegt PP, et al. (2001) The costs of head and neck oncology: primary tumours, recurrent tumours and long-term follow-up. *Eur J Cancer* 37: 2204–2211.
- 75) Govers TM, Takes RP, Baris Karakullukcu M, Hannink G, Merckx MA, et al. (2013) Management of the N0 neck in early stage oral squamous cell cancer: A modeling study of the cost-effectiveness. *Oral Oncology* 49: 771–777.
- 76) Scharukh Jalisi (2005) Management of the Clinically Negative Neck in Early Squamous Cell Carcinoma of the Oral Cavity. *Otolaryngol Clin N Am* 38: 37–46.
- 77) Weiss MH, Harrison LB, Isaacs RS (1994) Use of decision analysis in planning a management strategy for the stage N0 neck. *Arch Otolaryngol Head Neck Surg* 120: 699–702.
- 78) Andersen PE, Cambronero E, Shaha AR, Shah JP, et al. (1996) The extent of neck disease after regional failure during observation of the N0 neck. *Am J Surg* 172:689–691.
- 79) Collins SL (1999) Controversies in the management of cancer of the neck. In *Comprehensive management of head and neck tumors*. 2: 1479–1563.
- 80) Mendenhall WM, Million RR, Cassisi NJ (1980) Elective neck irradiation in squamous cell carcinoma of the head and neck. *Head Neck Surg* 3:15–20.
- 81) Fletcher GH (1984) Lucy Wortham James Lecture. Subclinical disease. *Cancer* 53: 1274–1284.
- 82) K Harish (2005) Neck dissections: radical to conservative. *World J Surg Oncol* 3:21
- 83) Richtsmeier WJ (2003) Dissecting the “endoscopic neck”. *Arch Otolaryngol Head Neck Surg* 129: 612.
- 84) Genden EM, Ferlito A, Bradley PJ, Rinaldo A, Scully C (2003) Neck disease and distant metastases. *Oral Oncol* 39: 207–212.
- 85) Leite ICG, Koifman S (1998) Survival analysis in a sample of oral cancer patients at a reference hospital in Rio de Janeiro, Brazil. *Oral Oncol* 34: 347–352.
- 86) Tiwari R (2000) Squamous cell carcinoma of the superior gingivolabial sulcus. *Oral Oncol* 36: 461–465.
- 87) O-charoenrat P, Pillai G, Patel S, Ficher C, Archer D, et al. (2003). Tumor thickness predicts cervical nodal metastases and survival in early oral tongue cancer. *Oral Oncol* 39: 386–390.



- 88) Kiran B Jadhav, Nidhi Gupta (2013) Clinicopathological Prognostic Implicators of Oral Squamous Cell Carcinoma: Need to Understand and Revise. *N Am J Med Sci* 5: 671–679.
- 89) Vural E, Hutcheson J, Korourian S, Kechelava S, Hanna E (2000) Correlation of neural cell adhesion molecule with perineural spread of squamous cell carcinoma of head and neck. *Otolaryngol Head Neck Surg* 122:717–720.
- 90) Fagan J, Collins B, Barnes L (1998) Perineural invasion in squamous cell carcinoma of head and neck. *Arch Otolaryngol Head Neck Surg* 124: 637–640.
- 91) Larsen SR, Johansen J, Sorensen JA, Krogdahl A (2009) The prognostic significance of histological features in Oral Squamous Cell Carcinoma. *J Oral Pathol Med* 38: 657–662.
- 92) Wong CY, Helm MA, Kalb RE, Helm TN, Zeitouni NC (2013) The presentation, pathology, and current management strategies of cutaneous metastasis. *North Am J Med Sci* 5: 499–504.
- 93) Chung CH, Parker JS, Karaca G, Wu J, Funkhouser WK, et al. (2004) Molecular classification of head and neck squamous cell carcinomas using patterns of gene expression. *Cancer Cell* 5: 489–500.
- 94) O'Donnell RK, Kupferman M, Wei SJ, Singhal S, Weber R, et al. (2005) Gene expression signature predicts lymphatic metastasis in squamous cell carcinoma of the oral cavity. *Oncogene* 24: 1244–1251.
- 95) Warner GC, Reis PP, Jurisica I, Sultan M, Arora S, et al. (2004) Molecular classification of oral cancer by cDNA microarrays identifies overexpressed genes correlated with nodal metastasis. *Int J Cancer* 110: 857–868.
- 96) Roepman P, Wessels LF, Kettelarij N, Kemmeren P, Miles AJ, et al. (2005) An expression profile for diagnosis of lymph node metastases from primary head and neck squamous cell carcinomas. *Nat Genet* 37:182–186.
- 97) Roepman P, Kemmeren P, Wessels LF, Slootweg PJ, Holstege FC (2006) Multiple robust signatures for detecting lymph node metastasis in head and neck cancer. *Cancer Res* 66: 2361–2366.
- 98) van Hooff SR, Leusink FK, Roepman P, Baatenburg de Jong RJ, Speel EJ, et al. (2012) Validation of a Gene Expression Signature for Assessment of Lymph Node Metastasis in Oral Squamous Cell Carcinoma. *J Clin Oncol* 30: 4104–4110.
- 99) Solal-Céligny P, Roy P, Colombat P, White J, Armitage JO, et al. (2004). Follicular lymphoma international prognostic index. *Blood* 104:1258–1265.
- 100) Sehn LH, Berry B, Chhanabhai M, Fitzgerald C, Gill K, et al. (2007). The revised International Prognostic Index (R-IPI) is a better predictor of outcome than the standard IPI for patients with diffuse large B-cell lymphoma treated with R-CHOP. *Blood* 109: 1857–1861.
- 101) Liao CT, Huang SF, Chen IH, Chang JT, Wang HM, et al. (2009) Risk stratification of patients with oral cavity squamous cell carcinoma and contralateral neck recurrence following radical surgery. *Ann Surg Oncol* 16: 159–170.
- 102) Hsieh YY, Mu-Hsin Chang P, Chen MH, Chu PY, Tzeng CH, et al. (2011) Pretreatment risk stratification for non-metastatic head and neck squamous cell carcinoma in a high-prevalence area. *Chin Med Assoc* 74: 487–492.

**Submit your manuscript to a JScholar journal and benefit from:**

- ¶ Convenient online submission
- ¶ Rigorous peer review
- ¶ Immediate publication on acceptance
- ¶ Open access: articles freely available online
- ¶ High visibility within the field
- ¶ Better discount for your subsequent articles

Submit your manuscript at  
<http://www.jscholaronline.org/submit-manuscript.php>